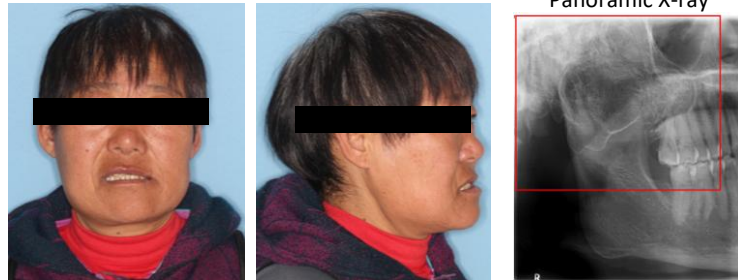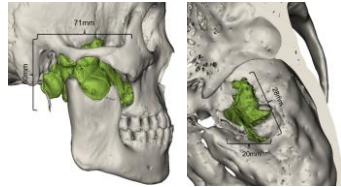


Customized TMJ-skull base combined prosthesis

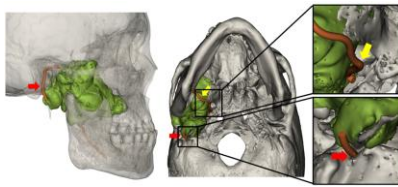
Preoperative



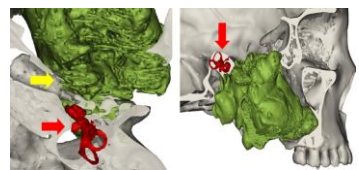
CT showed a skull base perforation



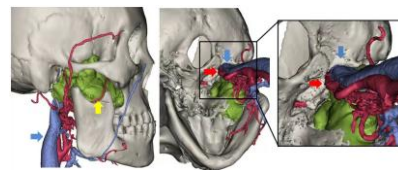
Relationship of tumor to the ear



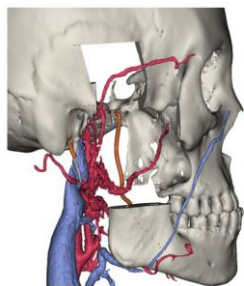
Relationship of tumor to nerves V and VII



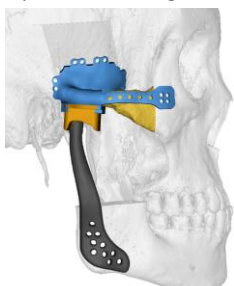
Relationship of tumor to vessels



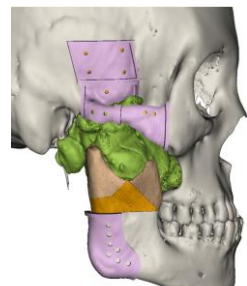
Defect model after resection



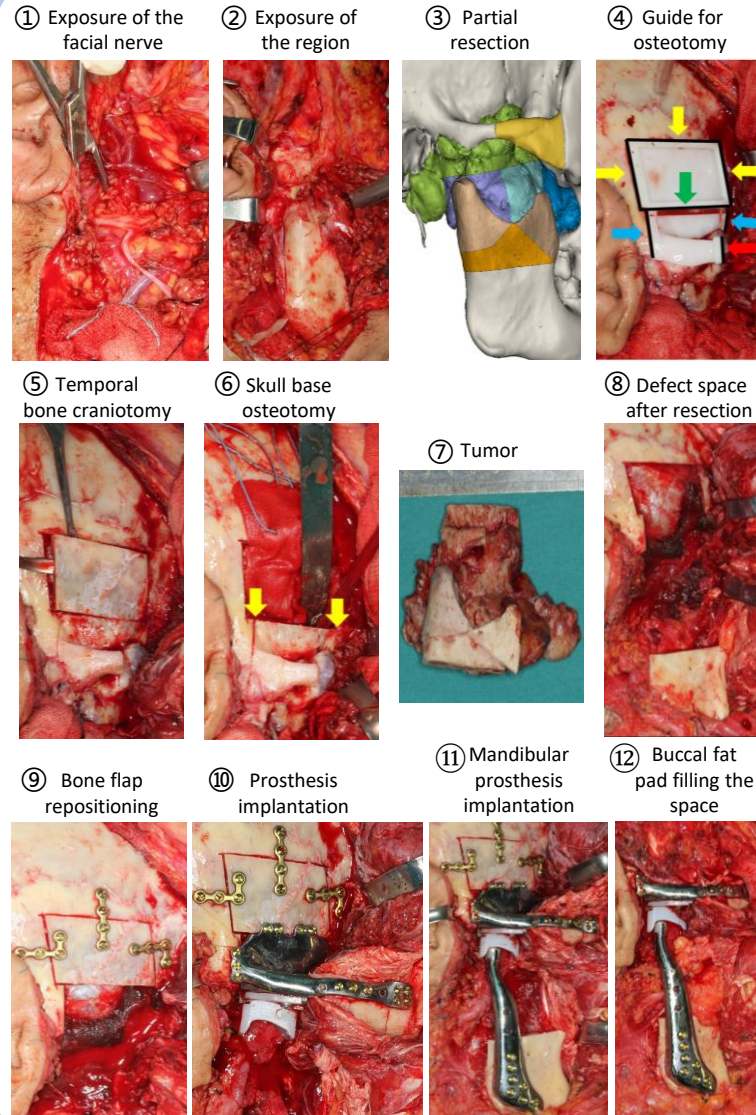
TMJ-skull base prosthesis design



Design of guide plates

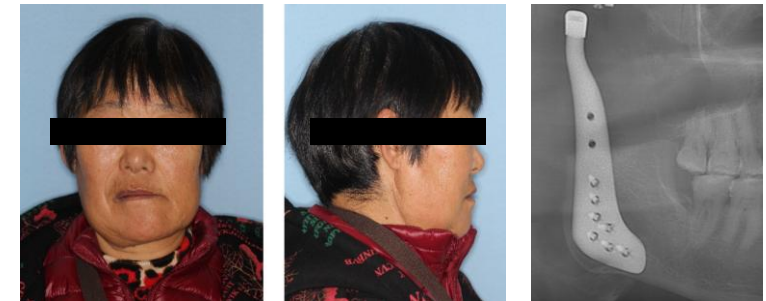

Operation

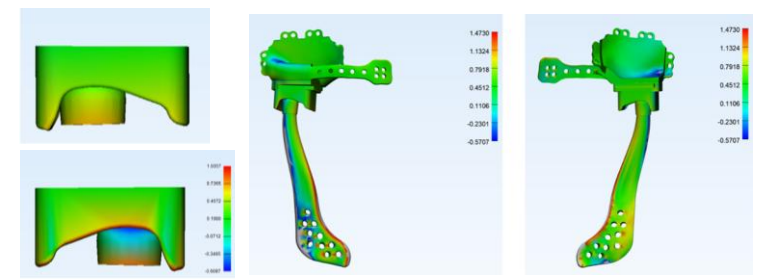


Postoperative

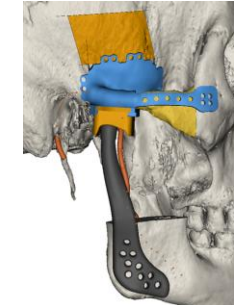
Five years after surgery



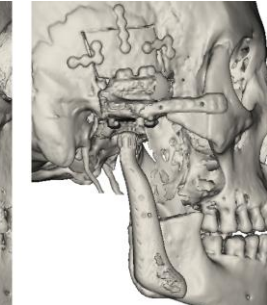
Prosthesis error evaluation



Preoperative prosthesis design



Immediate postoperative CT



Five year postoperative CT

